Evaluation of p16 immunostaining on fine needle aspiration in cervical lymph node metastasis in head and neck squamous cell carcinoma

Uma Handa, Dimple Kapoor, Reetu Kundu, Arjun Dass*

Departments of Pathology and *Otorhinolaryngology; Government Medical College and Hospital, Chandigarh, India

INTRODUCTION

- Head and neck squamous cell carcinoma (HNSCC) is the sixth most common malignancy worldwide. The overall incidence of HNSCC has decreased in the developed countries but in India, the incidence of HNSCC is high accounting for up to 40% of all malignancies.
- The most common sites of origin of head and neck carcinoma are those arising in the oral cavity and oropharynx.
- HNSCCs are of two types depending upon the etiology:
  - Conventional HNSCC is more prevalent among older men and is associated with traditional risk factors like alcohol consumption, tobacco use, environmental exposures, poor oral hygiene
  - Human papilloma virus (HPV) infection associated
- HPV is detected in 25%-45% cases of oropharyngeal HNSCC. More than 200 types of HPV have been identified, HPV-16 accounts for 85%-90% cases of HPV positive oropharyngeal HNSCC. HPV associated oropharyngeal HNSCC has been shown to be more responsive to therapy and has a better outcome than HPV negative tumors.
- Patients of HNSCC often present with a neck mass due to metastatic spread of tumor to the lymph nodes and cervical lymphadenopathy may be the first and only clinical manifestation. In about 3%-9% of patients, the primary site remains unknown even after detailed clinical, endoscopic and radiological search. Hence, HPV testing can be useful in the work-up of patients presenting with cervical metastasis and suspected to be of head and neck origin.
- The current study was planned to diagnose metastasis in cervical lymph node by fine needle aspiration (FNA) and to detect HPV positivity in squamous cell carcinoma using p16 immunocytochemistry.

  HPV status of lymph node metastasis was correlated with HPV status and histologic grade of the primary tumor.

MATERIALS AND METHODS

- The present study was conducted on 50 patients who presented with cervical lymphadenopathy and were diagnosed as metastatic squamous cell carcinoma on FNA. Patients with either known primary site of tumor in head and neck or those with primary detected after FNA of cervical lymph nodes were included.
- Patients on radiotherapy or chemotherapy and in whom histopathology of primary site was not available were excluded.
- FNA of the cervical lymph nodes was performed using 23G needle and in each case one-two passes were taken and 4-5 slides were made. For routine cytology, the smears were stained with May Grunwald giemsa (MGG) on air dried smears, hematoxylin and eosin (H&E) and Papanicolaou stain (Pap) on alcohol fixed smears. The cytological smears were interpreted for diagnosis and tumor typing.
- In cases diagnosed as metastatic squamous cell carcinoma on cytology, the surgical biopsy was received from primary site of tumor. Detailed microscopic examination was done for tumor diagnosis and tumor grading.
- Immunostaining for p16 was carried out on both cytological smears and histopathological tissue sections.
- On cytological smears p16 immunostaining was scored as positive when 50% or more cells showed strong and diffuse nuclear and cytoplasmic staining.
- For immunohistochemical expression of p16 on tissue sections, nuclear or cytoplasmic staining in >5% tumor cells was considered positive. It was quantified according to the percentage of tumor area stained:
  - grade1: 5-10%
  - grade 2: 10-30%
  - grade 3: 30-85%
- Results of p16 immunostaining in the metastatic cervical lymph node were correlated with histopathological examination of primary site.

RESULTS

Demographic details

- Forty six patients presented with ipsilateral and 4 with bilateral enlargement of lymph nodes.
- Age of the patients ranged from 35 to 80 years (mean 55.8±11.1) and male to female ratio was 6.1:1. Maximum number of patients 22 (44%) was in the age group of 51-60 years.
- The most common risk factor was smoking bidis/cigarettes/hukka (60%). Other predisposing factors were tobacco chewing or betel nut intake (44%) and alcohol intake (14%).

Cytological examination

- Out of 50 cases, 23 (46%) cases were keratinizing and 27 (54%) were non-keratinizing SCC.
- Smears showed scattered and clusters of anaplastic cells with evident orangeophilia and dense cytoplasm on Pap staining in keratinizing tumors. Background showed reactive lymphoid cells, macrophages, histiocytic giant cells and necrosis in variable proportions.

Histopathological examination

- The tumor from primary site was categorized as moderately differentiated in 38 (76%), poorly differentiated in 10 (20%) and well differentiated in 2 (4%) cases.
- The most common primary site of HNSCC was oropharynx in 25 cases followed by oral cavity in 14 and larynx in 11 cases. Amongst the oropharyngeal lesions, base of tongue was involved in 14 (28%) cases, followed by tonsil in 8 (16%) and vallecula in 3 (6%).
- The primary site of tumor was known in 38 (76%) cases at the time of lymph node metastasis and in 12 patients the primary site was located subsequent to the cytological diagnosis of cervical metastasis. In these 12 cases the primary site was oropharynx in 6, larynx in 4 and oral cavity in 2 cases.

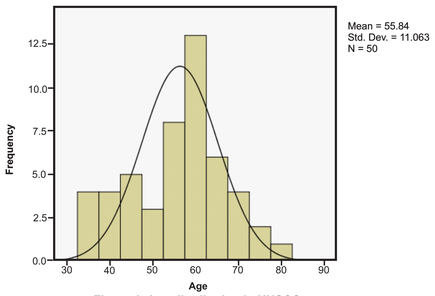

Figure 1. Age distribution in HNSCC

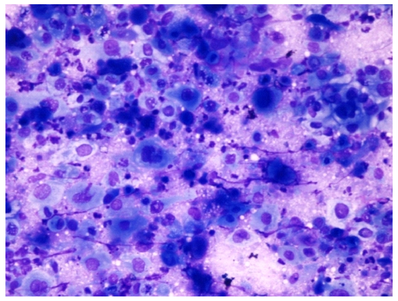

Fig. 4 Smear from metastatic keratinizing SCC showing singly scattered and loose clusters of tumor cells with hyperchromatic nuclei & dense cytoplasm (MGG x400)

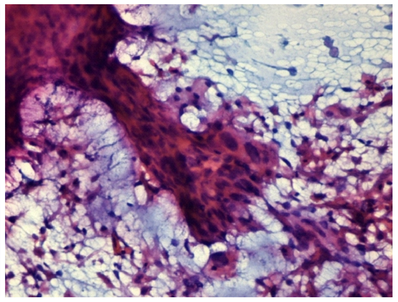

Fig. 5 Smear from metastatic SCCshowing sheet of keratinizing tumor cells (Pap x400)

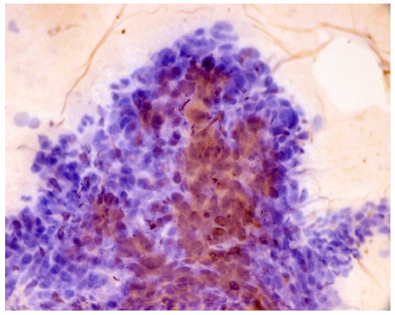

Fig. 6 Smear showing tumor cells exhibiting nuclear and cytoplasmic p16 positivity (ICC x400)

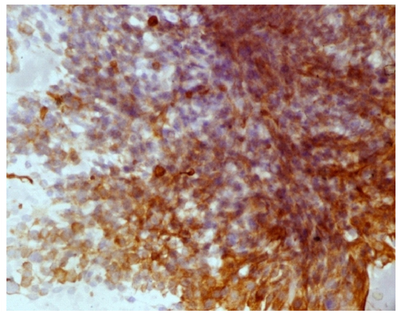

Fig. 7 Smear showing clusters of tumor cells exhibiting strong diffuse cytoplasmic positivity for p16 (ICC x400)

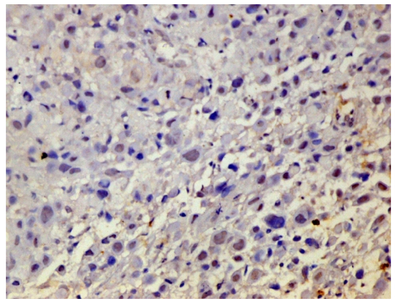

Fig. 8 Squamous cell carcinoma, moderately differentiated showing nuclear & cytoplasmic p16 positivity in 5-10% of tumor cells (Grade 1) (IHC x400)

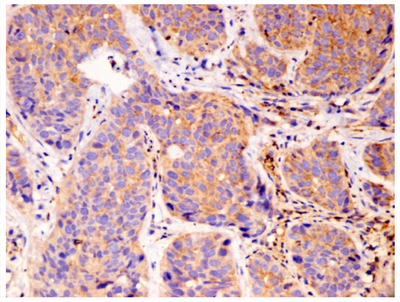

Fig. 9 SCC moderately differentiated showing diffuse cytoplasmic p16 positivity in >30% of tumor cells (Grade 3) (IHC x200)

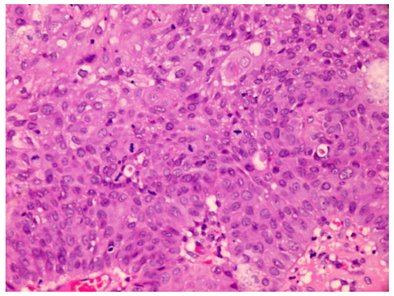

Fig. 10 Histopathology section from primary tumor site showing moderately differentiated squamous cell carcinoma (H&E x400)

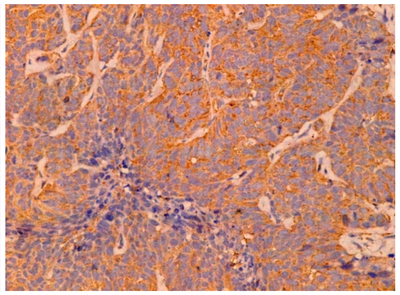

Fig. 11 Section from the same case showing diffuse p16 positivity in all the tumor cells (IHC x400)

p16 immunostaining

- The immunocytochemical (ICC) staining for p16 on smears showed positivity in 28 cases while 22 cases were negative (Table 1). Twelve (52.1%) out of 23 cases of keratinizing and 16 out of 27 cases of non-keratinizing metastatic squamous cell carcinoma were positive for p16. No significant association between presence and absence of keratinization was noted (p=0.014).
- On immunohistochemical (IHC) staining of primary tumor, p16 was positive in 34 cases and negative in 16 cases. Out of 34 positive cases; 8 (16%) were grade 1, 14 (28%) grade 2 and 12 (24%) were grade 3.
- All the cases that were positive for p16 on cytology were also positive for p16 on histopathology. There were 6 cases in which p16 ICC was negative but these were positive on IHC. There was a substantial agreement between the results on p16 ICC and IHC, with a kappa value of 0.823.
- The sensitivity of p16 for the detection of HPV in metastatic HNSCC was 82.4% while the specificity was 100%. The positive and negative predictive values were 100% and 72.7% respectively, with a diagnostic accuracy of 88%.
- Nineteen (76%) out of 25 cases located in oropharynx were p16 positive, 9 (81.8%) out of 11 laryngeal and 6 (42.9%) out of 14 cases of oral cavity were positive for p16, as shown in Table 2. A significant (p= <0.05) association of p16 positivity with oropharyngeal origin of HNSCC was found.
- On primary site of tumor, 29/38 cases of moderately differentiated and 5/10 cases of poorly differentiated SCC were positive for p16 IHC. None of the 2 cases of well differentiated SCC was p16 positive. A significant correlation between higher histological tumor grade and p16 positivity (p=0.031) was observed.

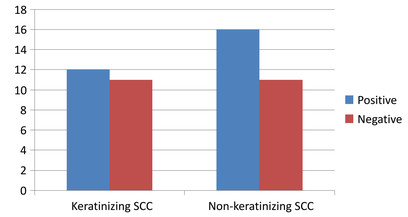

Figure 2. Correlation of p16 immunocytochemistry with cytological diagnosis

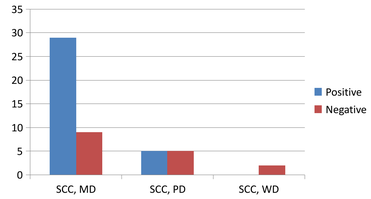

Figure 3. Correlation of p16 immunohistochemistry with differentiation of SCC in primary site of tumor

Table 1. Correlation of cytological diagnosis, p16 immunostaining & histopathological diagnosis

Cytologic diagnosis	*p16 ICC*	*Histopathologic diagnosis*	*p16 immunohistochemistry*
Keratinizing SCC (23)	Positive (12)	SCC, MD (12)	Positive (12) [Grade 1 (2), Grade 2 (5), Grade 3 (5)]
	Negative (11)	SCC, MD (08)	Positive (02), Negative (06) [Grade 2 (2)]
		SCC, WD (02)	Negative (02)
		SCC, PD (01)	Negative (01)
Non-keratinizing SCC (27)	Positive (16)	SCC, MD (12)	Positive (12) [Grade 1 (4), Grade 2 (5), Grade 3 (3)]
		SCC, PD (04)	Positive (4) [Grade 1 (1), Grade 2 (1), Grade 3 (2)]
	Negative (11)	SCC, MD (06)	Positive (03), Negative (03) [Grade 1 (1), Grade 3 (2)]
		SCC, PD (05)	Positive (1), Negative (4) [Grade 2 (1)]

Table 2. Association between tumor site & p16 immunohistochemistry

Site	p16 positive	p16 negative	No. of cases
Oropharynx	**19**	**6**	**25**
Oral cavity	**6**	**8**	**14**
Larynx	**9**	**2**	**11**
Total	**34**	**16**	**50**

DISCUSSION

- HNSCC is characterized by genetic heterogeneity, exhibiting a wide range of clinical presentation and is associated with high morbidity and mortality.
- HPV-positive HNSCC show an affinity for the oropharynx, especially the tonsils and the base of the tongue, and tend to show poor differentiation on histopathology. But they have better prognosis and it may be related to the immune system.
- HPV-positive HNSCC has a propensity to metastasize to cervical lymph nodes and in a significant number of patients neck mass may be the first and only clinical manifestation. Twelve patients (24%) in our study presented with metastases in cervical lymph node with unknown primary at the time of FNA. HPV analysis may help in detection of primary site of tumor in such cases.
- For detection of HPV, p16 acts as a surrogate marker. Methods which may be employed include IHC for p16, in-situ hybridization (ISH) and PCR. p16 immunostaining is relatively a simple method for determining HPV status. Classical p16 positive cases show strong diffuse nuclear and cytoplasmic expression.
- In the current study, p16 was positive in 28 cases by ICC at metastatic site and in 34 cases by IHC on the primary tumor site. A significant correlation of p16 positivity with the tumor differentiation was seen (p= 0.031). Twenty nine out of 38 cases of SCC, MD and 5/10 cases of SCC, PD were positive for p16. Thus p16 expression is more likely to be detected with higher tumor grade. Six cases were false negative on p16 immunocytochemistry due to scanty cellularity and necrotic background.
- Thus, FNA yields adequate material for p16 ICC and this may circumvent the need for more invasive sampling of primary tumor for HPV status.

CONCLUSIONS

- HPV testing should be incorporated into routine cytologic evaluation of metastatic SCC in cervical lymph nodes.
- p16 immunostaining serves as a surrogate marker for HPV and is helpful to pinpoint the primary tumor site.

REFERENCES

- Kreimer AR, Clifford GM, Boyle P, Franceschi S. Human papilloma virus types in head and neck squamous cell carcinomas worldwide: a systematic review. Cancer Epidemiol Biomarkers Prev 2005; 14: 467-75.
- Begum S, Gillison ML, Nicol TL, Westra W. Detection of human papilloma virus-16 in fine-needle aspirates to determine tumor origin in patients with metastatic squamous cell carcinoma of the head and neck. Clin Cancer Res 2007;13:1186-91.
- Hou Y, Chaudhary S, Shen R, Li Z. Fine-needle aspiration of cervical lymph nodes yields adequate materials for accurate HPV testing in metastatic head and neck squamous cell carcinomas. Diagn Cytopathol 2016; 44: 792-8.
- Xu B, Ghossein R, Lane J, Lin O, Katabi N. The utility of p16 immunostaining in fine needle aspiration in p16-positive head and neck squamous cell carcinoma. Hum Pathol 2016; 54: 193-200.